

THE SAFETY SIGNIFICANCE OF AIRCRAFT ACCIDENT POST MORTEM FINDINGS

P. V. Siegel, M.D.
S. R. Mohler, M.D.
A. Cierebiej, M.D.

Approved by

Stanley R Mohler
STANLEY R. MOHLER, M.D.
CHIEF, AEROMEDICAL APPLICATIONS
DIVISION

Released by

PV Siegel MD
P. V. SIEGEL, M.D.
FEDERAL AIR SURGEON

October 1969

Department of Transportation
FEDERAL AVIATION ADMINISTRATION
Office of Aviation Medicine

Prepared for the Seventh Scientific Session of the Joint Committee on Aviation Pathology, Halton, England, October 15, 1969. Dr. Siegel is Federal Air Surgeon, Federal Aviation Administration; Dr. Mohler is Chief, Aeromedical Applications Division, Office of Aviation Medicine, Federal Aviation Administration; and Dr. Cierebiej is Chief, Accident Investigation Branch, Office of Aviation Medicine, Federal Aviation Administration, Washington, D.C. 20590.

Qualified requesters may obtain Aviation Medical Reports from Defense Documentation Center. The general public may purchase from Clearinghouse for Federal Scientific and Technical Information, U.S. Dept. of Commerce, Springfield, Va. 22151.

THE SAFETY SIGNIFICANCE OF AIRCRAFT ACCIDENT POST MORTEM FINDINGS

I. Introduction.

We are all aware that in the early days of civil aviation, pathologists played an extremely minor role in aircraft accident investigation. This, of course, reflected, in part, the relatively limited role of civilian physicians in aviation activities prior to World War II. Subsequent to World War II, the pioneering achievements in aviation pathology carried out by military pathologists (in the United States, especially at the Armed Forces Institute of Pathology) have been documented.¹ Post mortem examinations of crew member victims of civil air transport aircraft accidents have achieved a level of virtually 100 percent. This achievement has resulted from the recognition by transport aircraft accident investigators that the findings of pathologists provide definitive information concerning the circumstances underlying aircraft accidents. This information covers causative factors as well as crash-injury and survival factors.

Unfortunately, a general recognition by various individuals involved in the investigation of light aircraft accidents of the contributions to be made by pathologists has not been realized to the fullest extent possible. We know of some recent fatal light plane accidents in which the investigators did not request post mortem examinations. This oversight, however, is being seen less frequently as a result of the recognition by accident investigators of the value of either positive or negative pathology findings. This paper will present some information on the current status of aircraft accident post mortem findings as these relate to air safety and will give special emphasis to such findings in those accidents which occur in the general aviation segment of civil flight activities.

II. Findings and Discussion.

The accident folders for the year 1968 contained in the Accident Investigation Branch of

the Office of Aviation Medicine were reviewed. It was found that there were records of 706 fatal general aviation accidents. Within this fatal accident population were 687 pilots. In 19 of the 706 fatal accidents, only passengers succumbed, thus the lesser number of fatal pilots in relationship to the number of fatal accidents. It was found that of these 687 pilot fatalities, 365 post mortem examinations were accomplished. It is seen, then, that in 1968, a 51 percent post mortem examination level was achieved in U.S. general aviation accidents.

Table 1 includes a sequential listing of pathologists' comments included in the autopsy records for the first 60 days of 1968. These comments come from pathologists in all sections of the U.S., and are representative of the terminology used by pathologists throughout the entire year. Special attention was given to extracting comments bearing specifically upon atherosclerosis, especially with respect to the coronary arteries. Since atherosclerotic changes in the coronary arteries ultimately can lead to sudden incapacitation, aeromedical personnel are particularly concerned about the extent to which this condition exists throughout the pilot population. It is noted that some pathologists utilize descriptive terminology such as "minimal atherosclerosis" (presumably on a scale of minimal, moderate, or severe). Others describe the atherosclerosis as having stenosed the lumen to 75 percent of normal. Some pathologists made no mention at all of the interior of the coronary arteries, either on their gross or microscopic examinations.

Because of the findings by the pathologist, many accidents each year are better understood. When the circumstances of the accident are considered together with the findings of a fresh occlusion of a coronary artery or severe coronary disease compatible with sudden heart failure, the investigators conclusions are essentially made. The following relatively recent case histories

serve as examples (there are several similar cases each year in the U.S.):

Case History Number One

A 44-year-old male pilot with 9,500 hours of flight experience and a commercial pilot's license was flying solo in a Cessna 210, February 21, 1968. As the airplane neared its destination (a midwest airport), the pilot called the airport tower controller and reported "having difficulty breathing and seeing." The airplane was observed to turn into the base leg somewhat fast and then to turn to the final approach. The plane proceeded above the runway for a distance at about 60 feet of altitude and then was seen to nose over to a 40° downward inclination and dive straight into the runway with no apparent effort on the part of the pilot to recover.

The post mortem examination revealed an "extremely narrow" left descending coronary artery, with the lumen "pinpoint in size for its entire length." The right circumflex coronary artery was reported "also narrow, with the wall thick and yellow."

The investigators felt that the pilot became physically incapacitated while attempting to land.

Case History Number Two

A 48-year-old male private pilot with 134 hours known flight time was flying alone in a Cessna 150 in the Southwest on April 8, 1969. The aircraft had departed the airport and was witnessed to suddenly enter a left bank from a low altitude and then to dive straight into the ground. No evidence of any attempt to pull out was seen.

The post mortem report states that "the interior descending branch of the left coronary artery 1 centimeter from the site of origin shows recent hemorrhage into the atherosclerotic plaque." It also states "this effectively occludes the narrowed lumen."

The investigators concluded that the pilot became totally incapacitated in flight, resulting in the fatal accident.

The above cases illustrate the discovery that coronary insufficiency at a given moment or coronary occlusion may yield a transient ischemia over a small part of the myocardium followed by a lethal arrhythmia with or without myocardial necrosis.² Improvements in electrocardiography

have made possible the premortem detection of compromised coronary arteries and, or, myocardial necrosis. Continuing information developed by pathologists is desired to augment these clinical techniques.

The post mortem examinations accomplished to date, together with the analyses of the circumstances related to general aviation accidents, lead us to the conclusion that approximately six in-flight cardiovascular incapacitations per year occur to pilots flying light planes.

The diversity of terminology currently used by pathologists reflects the lack of general application of a standardized format for autopsy accomplishments. If the valuable data being collected by aeromedical investigators in these accidents is to be analyzed on a broad scale, and if it is to be treated by computer-assisted techniques, some type of quantitative approach to post mortem data recording must now take place. We must know in each case the extent of atherosclerosis throughout the coronary artery bed. We must know the degree to which the lumen of the coronary artery is compromised. Also, this information must be expressed by pathologists as closely as possible in generally agreed upon mathematical terms. In addition, data must be recorded concerning whether or not a particular pathologic change was or was not present. It is observed that sometimes the cranial vault is not examined during the post mortem examination. This portion of the examination is considered to be quite significant.

It is noted that a number of pathologists in various parts of the country have developed their own standard format and have had forms printed. These forms serve as a guide during the conduct of the post mortem and comprise valuable systematic collection of data. Figure 1 illustrates a page from one example and Figure 2 illustrates another. Particularly clever, it seems to us, is the approach used in Figure 1 whereby the major coronary arteries are diagrammed on the form and atherosclerotic plaques sketched as found. Also, any deviation in coronary artery distribution can be shown.

We re-emphasize the need for pathological information which transcends the earlier predominantly verbal descriptive approach and takes on a computer-age quantitative character. Notable progress in obtaining post mortems has occurred,

but until quantitative descriptions are more generally available, a general analysis of post mortem data will necessarily be limited.

We would like to stress that the post mortem examination pertaining to aircraft accidents is both a "flight performance" examination and a forensic pathology examination. The findings may well be related to significant legal considerations. It is noted that if it is found that the large majority of pilots over the age of 40 contain significant coronary artery disease, then we must improve our physical examination methodology to enable detection of those persons who apply for medical certification who have advanced previously unknown disease.

We also emphasize that although significant pathology is divulged through the post mortem examination in a specific case, the role of this pathology (with respect to the cause of or as a contributor to the actual accident) can be determined only when all of the circumstances are reviewed and evaluated. It will often be concluded as in the majority of the cases reviewed here, that pathological findings are incidental to the specific accident (other than those findings resulting from the impact or fire).

An important additional consideration bearing upon the need for post mortem information concerning pilots of general aviation aircraft is that of the requirements for aeromedical certification.

Post mortem data is essential in order that the physical standards required for pilots can be routinely monitored for effectiveness.

III. Conclusions and Recommendations.

The next advance in aviation pathology studies is seen as the standardization of post mortem format and terminology. Especially needed today is a quantitative measure for the degree and extent of atherosclerosis. It is recommended that a standard format be promulgated by pathologists and utilized for the conduct of aviation post mortem examinations. It is also recommended that pathologists develop and utilize a quantitative scale for assessing the degree and extent of atherosclerosis, particularly that found in the coronary arteries.

TABLE 1—Summary of Sequential Post Mortem Data, Pilot Fatalities, 1/03/68 to 3/05/68 (Coronary Atherosclerosis)

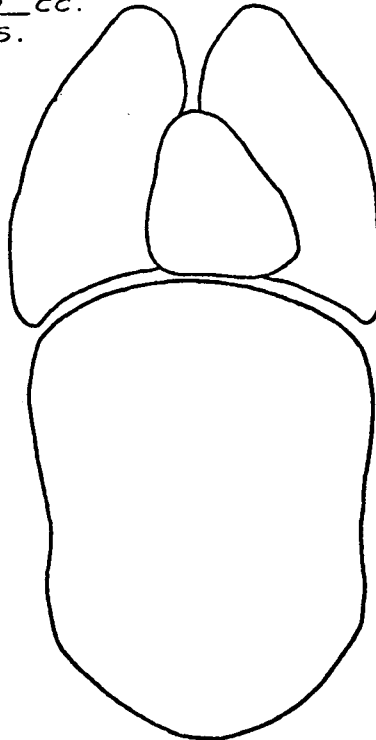
Age group	Coronary atherosclerosis		
	Absent	Present	No mention
20-29	2	3	1
30-39	1	6	2
40-49	2	12	3
50-60	1	2	0

REFERENCES

1. REALS, WILLIAM J. (Editor); *Medical Investigation of Aviation Accidents*, College of American Pathologists. Chicago, Illinois 1968, pp. 1-150.
2. PROGER, SAMUEL; Comment on "Coronary Heart Disease Terminology" *Journal of the American Medical Association*, Vol. 209, No. 8, August 25, 1969, pp. 1229-1230.

INTERNAL EXAMINATION:

RT. PLEURA 0 CC.
 FIBR. ADHES.



AUTOPSY NO.
A-7-62

LEFT PLEURA 0 CC.
 FIBR. ADHES.

MEDIASTINUM:

PERICARDIUM. 0 CC.
 FIBR. ADHES.

PERITONEAL CAVITY 0 CC.
 FIBR. ADHES.

RETROPERITONEUM: *No PATHOLOGICAL CHANGES DEMONSTRATED.*

~~ARTERIOSCLEROSIS~~

	0	SL.	MOD.	SEV.
AORTA		✓		
CORONARY				✓
CEREBRAL	✓			

CARDIOVASCULAR SYSTEM:

ACCESS. RT. CORONARY A.

ALL OF THE CORONARY ARTERIES HAVE EXTENSIVE INVOLVEMENT OF THE WALLS BY ARTERIOSCLEROTIC PLAQUE FORMATION. THE LUMINA ARE REDUCED TO APPROXIMATELY 8-90% NORMAL INTERNAL DIAMETER. NO FRANK OCCLUSION IS DEMONSTRATED.

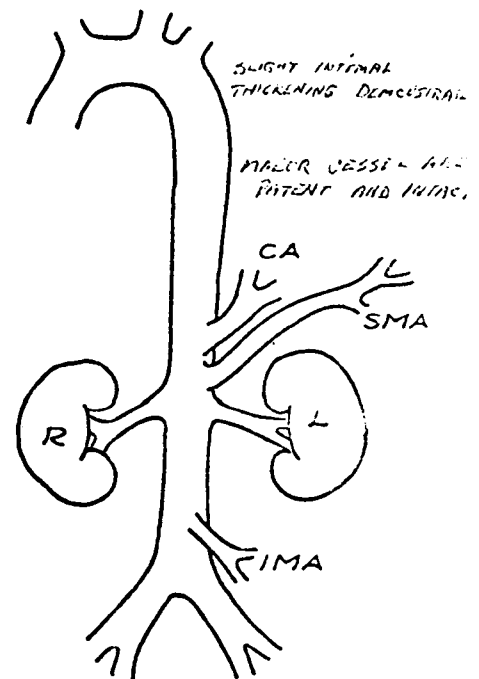
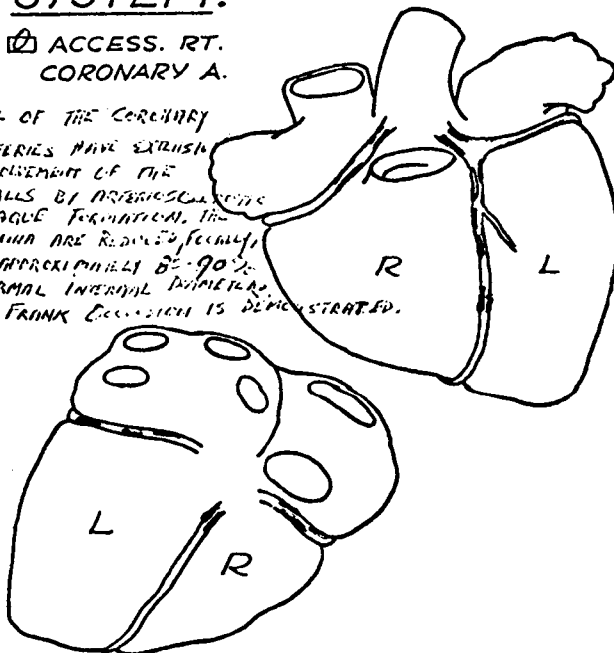


FIGURE 1. This form was devised by a pathologist to enable a more consistent and graphic portrayal of atherosclerosis findings. It is one of several pages completed by the pathologist for each post mortem examination.

ABDOMEN:

- Peritoneum
- Retroperitoneum
- Liver—Weight **1700 gm**
- Extrahepatic Ducts
- Gallbladder
- Spleen—Wt. **250 gm.**
- Esophagus
- Stomach
- Duodenum
- Small Bowel
- Large Bowel
- Pancreas
- Adrenals
- Right Kidney—Wt. **140 gm.**
Length **13.5 cm.**
Cortex **.7 cm.**
- Left Kidney—Wt. **140 gm.**
Length **11.6 cm.**
Cortex **.9 cm.**
- Right Ureter
- Left Ureter
- Bladder
- Urethra
- Prostate—Wt.
- Testicles—Wt.
- Uterus—Wt.
- Fallopian Tubes
- Ovaries

VASCULATURE:

- Ascending Aorta
 - Thoracic Aorta
 - Abdominal Aorta
 - Great Branches, Aorta
 - Great Veins
- Grade I atherosclerosis of aorta, patchy.**

CENTRAL NERVOUS SYSTEM:

- Not Examined
- Dura
- Leptomeninges
- Ventricular Fluid
- Dural Sinuses
- Pituitary Gland
- C.N.S. Arteries
- Coronal Brain Sections

X = no significant abnormality

O = see supplementary sheet

FIGURE 2. This page is from a standard format used by a pathologist to assist in the uniform and systematic collection of post mortem information. It helps assure that no system or organ is overlooked.

APPENDIX I
1968 FATAL GENERAL AVIATION ACCIDENTS
(Temporal Sequence Sample)

Accident number	Accident date	Age	Sex	Pilot hours	Pilot certificate	Medical certificate	Aircraft type	Accident site	Pathologist's atherosclerosis statement	Selected other findings	Circumstances	Comment
68-0001	1-03-68	46	Male	1,000	Private	Third	Luscombe	Michigan	The coronary ostia opened into their respective sinuses of Valsalva which showed marked atheromatous changes. Coronary ostia narrowed to approx. 60% of normal size.	Laceration of aorta and right ventricle. Right and Left ventricular hypertrophy. Laceration & maceration of frontal lobes and cerebellar surfaces.	Impossible to determine who was actually flying at time of accident. Student pilot in right seat. Occupants may have been spotting game. Weather CAVU.	Attempt made to quantitate degree of atherosclerosis.
68-0018	1-07-68	46	Male	200	Student	Third	Taylorcraft	Nebraska	Right coronary and descending branch of left coronary contain scattered atheromatous plaques. These have effected a reduction in the caliber of the right coronary to estimated 30% of normal and left coronary to estimated 30% of normal size. The coronary arteries are thin walled and appear normal.	Traumatic rupture of thoracic aorta and right ventricle with hemorrhax and cardiac tamponade.	Pilot undetermined. Student was in left seat. Occupants were spotting coyotes. Weather CAVU.	Attempt made to quantitate degree of atherosclerosis.
68-0029	1-06-68	22	Male	87	Private	Third	Cessna 150	S. Dakota	The coronary arteries are thin walled and appear normal.	Decapitation of upper head. Crushing injuries to chest and abdomen. 0.06% blood alcohol.	Pilot was practicing night landings. Impact with ground at a 45° nose down attitude. Weather clear, cold, calm.	No attempt made to quantitate degree of atherosclerosis.
68-0038	1-05-68	40	Male	520	Private	Third	Cessna 182	Texas	No mention made of coronary vessels or atherosclerosis at any site.	Body dressed in lacerated blue coveralls known as flying suit, worn over a T-shirt and trousers. Massive injuries consist of	Noninstrument rated pilot found himself in instrument weather. Cloudy, fog, drizzling rain, ceiling 150' 400' overcast visibility 3/4	Autopsy done at university hospital. Report consists of one paragraph dealing chiefly with dress and

68-0056	1-04-68	39	Male	172	Private	Third	Taylorcraft	Utah	<p>numerous skull fractures, numerous jaw fractures, marked distortion of face. Blood samples negative for CO, alcohol, barbiturates, and tranquilizers.</p> <p>Multiple fractures and lacerations. CO 8.1 volume percent.</p>	<p>mile, temp 57°, dew point 55. Outdated map. Flew into radio antenna.</p> <p>Aircraft struck ground with severe vertical force and twisting motion as if spinning. Weather clear, cold; visibility 10 miles.</p>	<p>fractures and laceration sites.</p> <p>No attempt made to quantitate degree of atherosclerosis.</p>
68-0079	1-03-68	45	Male	806	Private	Second	Mooney	Alabama	<p>Coronary arteries contain rare yellow plaques and are widely patent throughout. Intima of aorta is smooth and glistening and contains rare yellow plaques.</p> <p>Coronary vessels showed slight to moderate atherosclerotic changes. No occlusion. Kidneys showed moderate nephrosclerosis. Aorta showed marked atherosclerosis. Lungs showed focal collapse, focal edema, and thickened vessel walls.</p>	<p>Weather below VFR min. Drizzling rain. Non-instrument rated pilot. Indefinite ceiling 400'. Visibility 1 mile, fog.</p>	<p>Very coarse estimate of degree of atherosclerosis.</p>
68-0071	1-08-68	40	Male	10,900	Commercial	Second	Beech turboprop	California	<p>Injuries, multiple, extreme.</p>	<p>Aircraft turned right, nosed up and rolled over just after takeoff. Right engine failed. Weather CAVU.</p>	<p>Very coarse estimate of degree of atherosclerosis.</p>
68-0112	1-12-68	22	Male	50	Student	Third	Cessna 150	New York	<p>Fracture of skull, ribs, lower extremities, lacerations of liver, lung, heart with hemoperitoneum hemothorax, and cardiac tamponade.</p>	<p>Weather—high broken clouds, visibility 10 miles, aircraft started spin at about 1800' then took a 60° dive in water.</p>	<p>Very coarse estimate of degree of atherosclerosis.</p>

APPENDIX I—1968 FATAL GENERAL AVIATION ACCIDENTS (Temporal Sequence Sample)—Continued

Accident number	Accident date	Age	Sex	Pilot hours	Pilot certificate	Medical certificate	Aircraft type	Accident site	Pathologist's atherosclerosis statement	Selected other findings	Circumstances	Comment
68-0117	1-20-68	41	Male	7,113	ATR	First	Piper PA-31	N. Carolina	Aorta intima is smooth and uniformly yel'w. No atherosclerosis.	Multiple large lacerations, fractures and extensive third degree burns.	Weather CAVU. Brand new aircraft developed right spin, crashed into ground and burned.	Presence of atherosclerosis denied in autopsy protocol. No mention of atherosclerosis
68-0137	1-19-68	42	Male	122	Student	Third	Temco	California	Coronary arteries arise in usual locations, have normal distributions & are grossly not remarkable as are endocardial surfaces and cardiac valves.	Ruptured aorta, fractured ribs & spine. Pilot was diabetic, obtained license under false pretenses and suspension of license was recommended before accident.	Weather hazy, ceiling high, visibility 5 miles Fuel starvation. Main tank full but selector valve set on auxiliary which was dry.	No mention of atherosclerosis
68-0154	2-06-68	48	Male	1,000	Commercial	Second	Cessna 150	Penna	Coronaries and aorta mildly atherosclerotic. No evidence of coronary thrombosis and/or occlusion.	Multiple skull fractures, lacerations & contusion of brain.	Weather CAVU. Aircraft searching for lost model airplane. Lost control at extremely low altitude.	Crude attempt to quantitate degree of atherosclerosis.
68-0174	1-20-68	36	Male	6	None	None	Home-built	California	Coronary arteries are firm and patent throughout.	Multiple traumatic injuries.	Weather CAVU. Uncertified pilot flying uncertified homebuilt gyrocopter, failed to maintain adequate flying speed.	No mention of atherosclerosis.
68-0205	1-21-68	43	Male	844	Private	Third	Cessna 172	Indiana	No mention made of coronary vessels or atherosclerosis at any site.	Organs of chest and abdomen mutilated and displaced. Blood alcohol 44 mg.%, urine alcohol 135 mg.%	Weather—fog, cloudy, ceiling zero, visibility 300'. Noninstrument rated pilot had been drinking, went flying in severe instrument weather.	No mention of atherosclerosis.
68-0241	1-11-68	25	Male	151	Private	First	Cessna 150	Washing-	Very little atheroma in aorta and none seen in coronary arteries.	Hemopneumothorax ruptured lungs and heart.	Weather—cloudy, rain, ceiling 3,000, visibility 20 miles. Engine failure in flight attributed to carburetor icing.	Crude estimate of atherosclerosis.

68-0242	1-14-68	37	Male	1,295	Commercial	Second	Piper 13	S. Dakota	The coronary arteries have thin walls with no evidence of atheroma.	Multiple traumatic injuries.	Weather hazy, ceiling 8,000', visibility 4 miles. Went fox hunting and apparently lost control at low altitude.	Presence of atherosclerosis denied.
68-0255	2-0-68	58	Male	12,600	ATR	First	Thorp-T-18	Texas	There was significant atherosclerotic disease involving the proximal segments of the coronaries.	Malignant lymphoma, obesity, extensive fractures and soft tissue lacerations.	Weather CAVU. Stabilator torque tube failed on flight of homebuilt aircraft.	No attempt made to quantitate degree of atherosclerosis.
68-0282	1-28-68	53	Male	4,055	Commercial	Second	Beech-B-95	Alabama	The coronary vessels are dissected and show no coronary arteriosclerosis or occlusion.	Multiple rib fractures penetrating plura; hemopneumothorax. Rupture of aorta.	Weather CAVU. Aircraft crashed after attempting a go-around after hard landing.	Presence of atherosclerosis denied.
68-0300	2-04-68	55	Male	5,400	Commercial	Second	Cessna 150	California	Aorta shows only nominal lipid infiltration of the superficial media in a few areas. Nominal atherosclerosis in normally formed coronary arterial tree.	Hemorrhage about the brain and upper spinal cord. Blood alcohol 0.25%	Weather CAVU. Intoxicated pilot flying at night. Instrument lights out. Pilot became lost and disoriented, crashed after fuel exhausted.	No attempt to quantitate degree of atherosclerosis.
68-0311	1-19-68	24	Male	255	Commercial	Class 1	PA 32/300	California	Coronary arteries only minimally involved with subintimal atherosclerotic changes. Aorta elastic and free of any atherosclerotic changes.	Multiple and severe cerebral contusions. Subarachnoid hemorrhage. Massive retroperitoneal hemorrhage.	Weather CAVU. Pilot apparently mistook carburetor mixture control for prop pitch control as mixture was full lean.	No attempt to quantitate atherosclerotic changes.
68-0347	2-14-68	37	Male	477	Commercial	Class 1	Cessna 172H	New Hampshire	Few small lipid plaques in the intima of the major coronary trunks. Coronary lumina are ample.	Multiple traumatic injuries. Brain alcohol 0.19 percent.	Weather cloudy, ceiling 3000', visibility 15 miles. Intoxicated pilot lost control of aircraft.	No attempt to quantitate atherosclerotic changes.
68-0361	2-04-68	28	Male	300	Student	Class 3	Cessna 172G	Colorado	No mention made of coronary arteries or atherosclerosis at any site.	Multiple injuries, contusions, lacerations, and fractures.	Weather CAVU. Inexperienced pilot lost control of aircraft, probably because of downdrafts on lee side of mountains.	No mention made of atherosclerosis.
68-0370	2-25-68	24	Male	581	Commercial	Class 2	Callair A-3	California	No significant arteriosclerosis.	Thermal burns over body.	Weather CAVU. Pilot towing glider that	No attempt to quantitate

APPENDIX I—1968 FATAL GENERAL AVIATION ACCIDENTS (Temporal Sequence Sample)—Continued

Accident number	Accident date	Age	Sex	Pilot hours	Pilot certificate	Medical certificate	Aircraft type	Accident site	Pathologist's atherosclerosis statement	Selected other findings	Circumstances	Comment
68-0377	2-19-68	31	Male	2,072	Commercial flight instructor	Class 1	PA-23-250	New York	Coronary arteries are delicate, thin-walled and show yellow streaking. Minimal atheromatous yellow streaking of aorta.	Extensive fourth degree burns with carbonization.	became disengaged. Aircraft returned to land and stalled out during final approach. Weather cloudy. Ceiling 4500', visibility 12 miles. Both engines failed on takeoff.	atherosclerosis. No attempt to quantitate atherosclerosis.
68-0409	2-06-68	41	Male	700	Private	Class 3	Brantly B2B	Nebraska	Coronary arteries patent and normal except for a rare small atheromatous plaque. Aorta had a yellow intimal surface that contained an occasional atheromatous plaque.	Extensive crushing & mutilating injuries of entire body.	Weather CAVU. Damage to aircraft very extensive and cause of accident unknown.	No attempt to quantitate atherosclerosis.
68-0397	1-13-68	37	Male	1,105	Commercial	Class 2	Cessna 185	Washington	Minimal atheroma in aorta, none seen in coronary arteries.	Cerebral contusions, atelectasis, hemothorax, ruptured liver.	Weather foggy, cloudy, ceiling 200', visibility poor. Noninstrument pilot flew into severe instrument conditions.	No attempt to quantitate atherosclerosis.
68-0423	2-18-68	36	Male	1,628	Commercial & lighter-than-air free balloon	Class 1	Cessna 177	California	Few soft yellow intimal plaques in left anterior descending coronary stenosing lumen to perhaps 75% of normal caliber.	Obesity—288 lbs. Multiple extreme injuries. Ruptured thoracic aorta.	Weather CAVU. Pilot buzzing friend on ground.	Attempt made to quantitate degree of atherosclerosis.
68-0428	2-26-68	44	Male	900	Private	Class 3	Aero NCA 7BCM	California	Multiple sections of coronary vessels show minimal arteriosclerosis without evidence of obstruction or occlusion.	Multiple rib fractures. Lacerations of aorta, heart, liver, and spleen.	Weather CAVU. 2 min. after takeoff, aircraft banked sharply to right then nosed straight down to ground.	No attempt to quantitate atherosclerosis findings.

68-0437	1-08-68	43	Male...	2,256	Commercial	Class 2....	Cessna 180H	Alaska...	Coronary tree essentially free of atheromatous plaques. Aorta is remarkably free of atheromatous changes.	Bilateral hemothorax, avulsion right renal artery. Multiple fractures and lacerations.	Ceiling indefinite—300'. Visibility ½ mile, night, fog. Non-instrument pilot became disoriented in fog bank.	No attempt to quantitate atherosclerosis findings.
68-0468	2-21-68	44	Male	9,500	Commercial	Class 2....	Cessna 210-5	Michigan	Left descending coronary is extremely narrow. Lumen pinpoint for entire length. Right circumflex also narrow, wall thick & yellow. Aorta shows few raised yellowish plaques but coronary ostia are widely patent.	Arteriogram showed occlusion of right internal carotid artery. Pilot did not recover from surgery to relieve it.	Weather 4,000, broken. Visibility 10 miles. Pilot reported difficulty breathing and seeing on landing.	Coarse attempt to quantitate atherosclerosis findings.
68-0481	1-29-68	42	Male...	6,200	Commercial	Class 1....	Beech D18S	Nebraska	Coronary arteries contain only tiny atheromas, none more than 1 or 2 mm. in diameter. Minimal atherosclerosis in abdominal portion of aorta.	Rupture of major vessels around pulmonary hilar areas.	Weather foggy light rain, ceiling 600', visibility ¾ mile. Mail flight encountered weather below landing minimum. Pilot lost control of aircraft on landing.	Attempt to quantitate atherosclerosis findings.
68-0511	2-20-68	40	Male...	1,193	Private...	Class 3....	Beech E-35	Illinois	Right & left coronary no appreciable atherosclerosis. Anterior descending shows small yellow-gray plaques. Circumflex shows mild atherosclerosis. Mild atherosclerosis of aorta.	Blood alcohol 0.2%. Severe injuries of head and chest.	Weather cloudy, light snow. Ceiling 2,800', visibility 3 miles. Pilot under influence of alcohol and lost control of aircraft on landing.	No attempt to quantitate atherosclerosis findings.
68-0531	3-05-68	33	Male	72.9	Private...	Class 3	PA-28-180	Colorado	Coronaries exhibit eccentric deposits of atherosclerotic material but lumens do not appear significantly compromised at any point.	Contusions and lacerations of lungs.	Weather CAVU. Aircraft encountered spin stall during sightseeing flight.	No attempt to quantitate atherosclerosis findings.

APPENDIX I—1968 FATAL GENERAL AVIATION ACCIDENTS (Temporal Sequence Sample)—Continued

Accident number	Accident date	Age	Sex	Pilot hours	Pilot certificate	Medical certificate	Aircraft type	Accident site	Pathologist's atherosclerosis statement	Selected other findings	Circumstances	Comment
68-0438	1-21-68	46	Male	111	Student	Class 3	Piper J3C-65	Wisconsin	Coronary atheromatosis Gr. II. Aortic atheromatosis Gr. I.	Traumatic brain contusions.	Weather CAVU. Student pilot attempted steep turn at low altitude and stalled out.	Attempt made to quantitate degree of atherosclerosis.
68-0543	1-30-68	43	Male	1,100	Private	Class 3	Stinson 108-2	Texas	Coronary atherosclerosis, severe with near total occlusion of left & right coronaries.	Asphyxia due to drowning.	Weather cloudy, rain, ceiling 1200', visibility 5 miles. Low pass over lake and hit power lines.	Attempt made to quantitate degree of atherosclerosis.
68-0546	2-18-68	50	Male	1,860	Student	Class 3	Cessna 128J	Florida	Coronary vessels patent with minimal atherosclerotic changes.	Severe contusion to brain and crushing injuries to body.	Weather cloudy, rain, fog, ceiling low/visibility poor. Night, student pilot tried to follow highway in poor weather but touched down in field and rolled into woods.	No attempt to quantitate degree of atherosclerosis.

